

Optimizing the ultrasound visualization of the endometrial-myometrial junction (EMJ)

A. VOTINO^{1,2}, T. VAN DEN BOSCH¹, A.J.F. INSTALLÉ^{3,4}, D. VAN SCHOUBROECK¹, J. KAIJSER¹, Y. KACEM², B. DE MOOR^{3,4}, C. VAN PACHTERBEKE², D. TIMMERMAN¹

¹Department of Obstetrics and Gynaecology, University Hospitals KULeuven, Leuven, Belgium; ²Brugmann Departments of Obstetrics and Gynaecology, University Hospital Brugmann, Brussels, Belgium; ³KU Leuven, Department of Electrical Engineering ESAT, STADIUS Centre for Dynamical Systems, Signal Processing and Data Analytics, Leuven, Belgium; ⁴iMinds Medical IT, Leuven, Belgium

Correspondence at: thierryvandenbosch1901@gmail.com

Abstract

Objectives: The aim of this study was to find the best 3D reconstruction technique to visualize the endometrial-myometrial junction (EMJ).

Methods: Retrospective observational study on 240 stored 3D volumes of 80 patients. The first author reconstructed the 2D midcoronal image without volume contrast imaging (VCI), with VCI set at 4 mm and with VCI set at 2 mm. Three images per patient (240 images) were saved and integrated in the web-based electronic data capture software Clinical Data Miner (CDM) (<http://cdm.esat.kuleuven.be>). Five experienced gynaecologists analysed the images shown in random order. They scored the image quality (good, moderate, poor, insufficient) and described the EMJ of these images using IETA terminology (regular, irregular, interrupted, not defined). One of the examiners (CVP) also re-evaluated the same set of images after 12 days to assess intra-observer variability.

Results: The use of VCI significantly improved the recorded subjective image quality. The Fleiss' kappa coefficient for evaluating the inter-observer variability of the EMJ description using coronal view without VCI, with VCI at 4 mm and VCI at 2 mm were 0.36 ± 0.05 , 0.34 ± 0.05 and 0.42 ± 0.05 , respectively. The corresponding figures for the intra-observer variability were 0.58 ± 0.08 , 0.36 ± 0.08 and 0.68 ± 0.07 , respectively.

Discussion: In this study on 3D reconstructed coronal images of the uterine cavity, the 2 mm VCI slices gave the best quality images of the EMJ.

Key words: Ultrasonography, uterus, endometrial-myometrial junction, volume contrast imaging (VCI), 3D ultrasound, adenomyosis.

Introduction

Until recently, the assessment of the endometrial-myometrial junctional zone (EMJ) was mainly used on magnetic resonance images (MRI) for the diagnosis of adenomyosis (Hricak et al., 1983). The EMJ can also be visualized on high-resolution transvaginal 2D and 3D ultrasound. However, on ultrasound the EMJ is not always easy to display and there are currently no strict guidelines on how to analyse the EMJ. Only few studies on 3D imaging of the EMJ have been published (Alcazar et al., 2009; Exacoustos et al., 2011; Naftalin et al., 2012). A proper visualization of the EMJ is deemed to be important in the diagnosis of adenomyosis (Bromley

et al., 2000; Dueholm, 2006), myometrial invasion in endometrial cancer, the extension of submucous fibroids and the exact character of congenital uterine anomalies (Naftalin et al., 2009). A standardized sonographic evaluation of the EMJ is therefore important in order to study its relevance in such endometrial and myometrial diseases.

Volume Contrast Imaging (VCI) is a technology based on a volume acquisition technique that leads to contrast enhancement and speckle suppression in the two-dimensional ultrasound image. The use of VCI improves the contrast in ultrasound images (Henrich and Stupin, 2011; Jantarasengaram et al., 2014) and may offer a better assessment of size, margins and aspect of EMJ. VCI is quickly

performed and requires less training than 3D rendering.

The aim of this study was to evaluate which 3D reconstruction technique allows for optimal visualization of the EMJ on 3D stored images.

Methods

3D volumes from 183 consecutive patients who presented at the Leuven University Hospital bleeding clinic were selected in decreasing chronological order from 2009-2010 database. The protocol was approved by the local Ethics Committee of the University Hospitals Leuven and patients had given informed consent. The 3D volumes were collected using a Voluson E8 (GE Healthcare Ultrasound, Milwaukee, WI, USA) with a 6-12 MHz transvaginal probe. Out of the 183 cases, 65 cases with incomplete data were excluded. Of the remaining 118 3D volumes, the first author scored the image quality of the EMJ, for each reconstructed image without the use of VCI, as good (the EMJ is clearly visible and can be evaluated on the fundal, right lateral and left lateral borders), moderate (one border is not clearly visible), poor (two borders are not clearly visible) or insufficient (none of the borders are clearly visible). After exclusion of 38 cases because of insufficient image quality, 80 patients (study group) were selected for further analysis.

For each 3D volume, the uterus was examined in the sagittal plane to identify the cervical canal and the uterine cavity, and after complete rotation of 360°, the first author reconstructed the best image on 2D midcoronal plane without VCI, with VCI set at 4 mm and with VCI set at 2 mm.

The coronal view was obtained by placing the dot into the endometrial stripe on the sagittal and transverse views (plane A and B of the multiplanar

view). The multiplanar view was then adjusted until a satisfactory coronal image was obtained of both the endometrial cavity and the external uterine contour. The gradient light and sepia settings were used to optimize the view of the EMJ, which was visualized as a hypoechoic area surrounding the endometrial cavity.

For each 3D volume, 3 images in the coronal plane were reconstructed (2D coronal plane without VCI, with VCI 4 mm and VCI 2 mm), resulting in 240 images. Together with a questionnaire pertaining to these images, they were integrated into the web-based electronic data capture software Clinical Data Miner (CDM) (Installé et al., 2014) (<http://cdm.esat.kuleuven.be>).

Five gynaecologists with experience in gynaecological ultrasound used CDM to evaluate the questionnaire for all images, which were shown in random order to each examiner. The questionnaire comprised two questions.

In the first question, examiners reported image quality as good, moderate, poor, or insufficient, encoded as 4, 3, 2, and 1, respectively. These values were then averaged for the different technologies. Significance of differences in reported quality for the different technologies were assessed using paired t-tests.

In the second question, examiners assessed the EMJ of these images using IETA terminology (Leone et al., 2010), as regular, irregular, interrupted, or not defined, with one examiner (CVP) re-evaluating the same set of images after 12 days. These evaluations were used to calculate both inter- and intra-rater agreement, by means of Fleiss' kappa coefficient (Fleiss et al., 1971). The jackknife technique was used to determine confidence intervals for the kappa coefficient values.

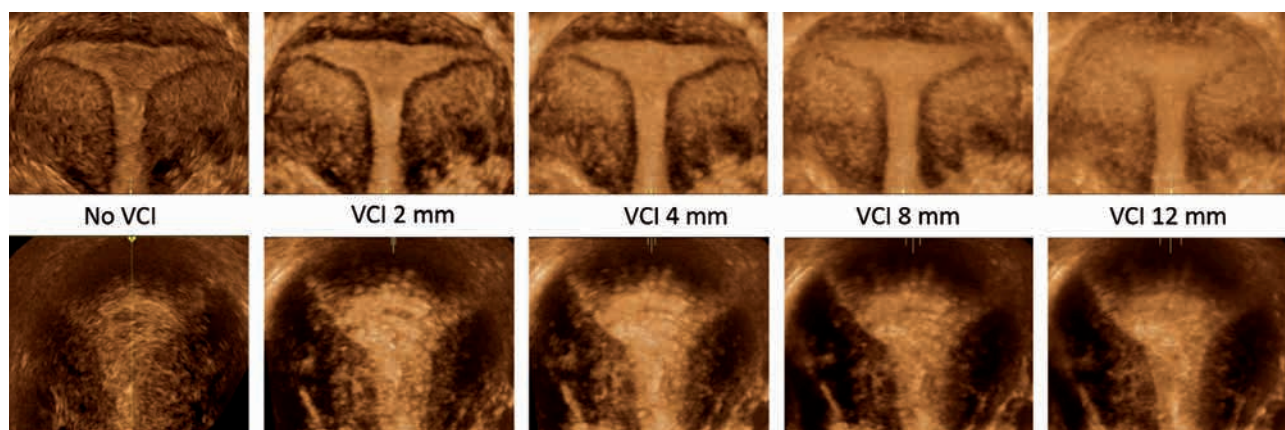


Fig. 1. — Coronal plane without Volume Contrast Imaging (VCI), with VCI 2 mm, VCI 4 mm, VCI 8 mm and VCI 12 mm. Note that using thicker VCI slices causes blurring, deteriorating the image quality.

Upper row: regular endometrial-myometrial junction.

Lower row: patient with adenomyosis. Note the irregular endometrial-myometrial junction (especially in the fundus).

Results

Compared to the coronal view without VCI, the use of both 4 mm and 2 mm VCI improved subjective image quality reported by participants ($p < 0.001$).

The Fleiss' kappa coefficient for evaluating the inter-rater agreement of the EMJ description using coronal view without VCI, with VCI at 4 mm and VCI at 2 mm were 0.36 ± 0.05 , 0.34 ± 0.05 and 0.42 ± 0.05 , respectively.

The corresponding figures for the intra-rater agreement for EMJ were 0.58 ± 0.08 , 0.36 ± 0.08 and 0.68 ± 0.07 , respectively. The use of VCI 2 mm im-

proved inter-rater and intra-rater agreement of EMJ description ($p < 0.001$), while VCI 4 mm did not.

Discussion

This study demonstrates that the visualization of the EMJ in the coronal plane using VCI 2 mm outperforms VCI 4 mm and 2D coronal plane without VCI. Using thicker VCI slices causes blurring, deteriorating the image quality (Fig. 1). Likewise, if 3D-rendering is used, the best images of the EMJ will be obtained using a thin region of interest (ROI) box (Fig. 2).

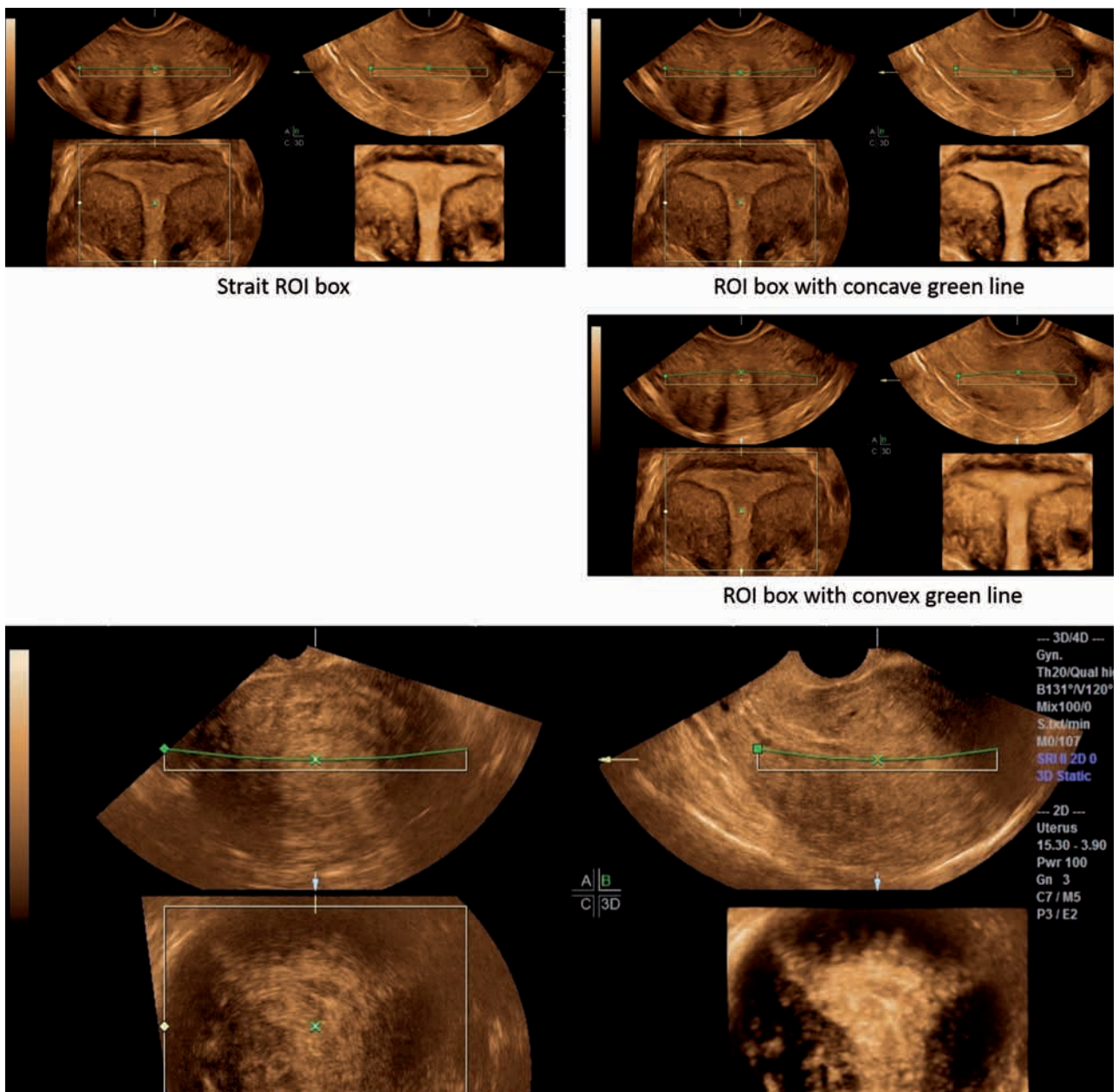


Fig. 2. — 3D-rendering of the endometrial-myometrial junction (EMJ) in a normal uterus (top three images) and in a patient with adenomyosis (bottom image): a thin region of interest (ROI) box is chosen. To enhance the image quality the green line can be bent to make the ROI box even thinner (ROI box with concave green line). If the ROI box is made thicker (ROI box with convex green line) the borders of the EMJ become blurred. In the adenomyosis case (bottom): note the irregular endometrial-myometrial junction (especially in de fundus) and the difference in image quality between the C-plane (2D without VCI) and the rendered 3D image.

Exacoustos et al., 2011) proposed the use of VCI 2 and 4 mm in the evaluation of the EMJ. Additionally, we have shown that the image quality of VCI 2 mm is superior to that of VCI 4 mm.

Naftalin et al., 2012) studied the inter- and intra-rater agreement in three-dimensional ultrasound assessment of the EMJ. They scored the quality of visualization of the EMJ by coronal view obtained using render mode as optimal, satisfactory or unsatisfactory. Their results showed good inter- and intra-rater variability with kappa values of 0.77 and 0.83 respectively. In our study the results using VCI 2 mm were 0.42 and 0.68, respectively. These differences may be explained by the fact Naftalin et al., 2012) tested 30 volumes of normal uteri only. Moreover our study addressed the issue of the clinical relevance by evaluating the inter- and intra-rater agreement in reporting the EMJ according to the IETA terminology (Leone et al., 2010).

The use of a standardized technique facilitates the dialogue between different observers and allows to evaluate the diagnostic relevance of ultrasound images of the EMJ, e.g. in the evaluation of adenomyosis, endometrial cancer, fibroids and congenital uterine anomalies. We propose to use VCI 2 mm in future studies evaluating the EMJ.

Acknowledgement

D. Timmerman is a senior clinical investigator of Scientific Research Fund (FWO) Flanders.

References

Alcazar JL, Galvan R, Albela S et al. Assessing myometrial invasion of endometrial cancer: uterine virtual navigation with three-dimensional US. *Radiology*. 2009;250:776-83.

- Bromley B, Shipp TD, Benacerraf B. Adenomyosis: Sonographic findings and diagnostic accuracy. *Ultrasound Med*. 2000;19:529-34.
- Dueholm M. Transvaginal ultrasound for diagnosis of adenomyosis: a review. *Best Pract Res Clin Obstet Gynaecol*. 2006;20:569-82.
- Exacoustos C, Brienza L, Di Giovanni A et al. Adenomyosis: three-dimensional sonographic findings of the junctional zone and correlation with histology. *Ultrasound Obstet Gynecol*. 2011;37:471-9.
- Fleiss JL. Measuring nominal scale agreement among many raters. *Psychological Bulletin*. 1971;76:378-82.
- Henrich W, Stupin JH. 3D volume contrast imaging (VCI) for the visualization of placenta previa increta and uterine wall thickness in a dichorionic twin pregnancy. *Ultraschall Med*. 2011;32:406-11.
- Hricak H, Alpers C, Crooks LE et al. Magnetic resonance imaging of the female pelvis: initial experience. *AJR*. 1983;141:1119-28.
- Installé AJF, Van den Bosch T, De Moor B et al. Clinical Data Miner: An Electronic Case Report Form System With Integrated Data Preprocessing and Machine-Learning Libraries Supporting Clinical Diagnostic Model Research. *JMIR Med Inform*. 2014; 2(2):e28. (DOI: 10.2196/medinform.3251).
- Jantarasengaram S, Praditphol N, Tansathit T et al. Three-dimensional ultrasound with volume contrast imaging for preoperative assessment of myometrial invasion and cervical involvement in women with endometrial cancer. *Ultrasound Obstet Gynecol*. 2014;43:569-74.
- Leone FP, Timmerman D, Bourne T et al. Terms, definitions and measurements to describe the sonographic features of the endometrium and intrauterine lesions: a consensus opinion from the International Endometrial Tumor Analysis (IETA) group. *Ultrasound Obstet Gynecol*. 2010;35:103-12.
- Naftalin J, Hoo W, Nunes N et al. Inter- and intraobserver variability in three-dimensional ultrasound assessment of the endometrial-myometrial junction and factors affecting its visualization. *Ultrasound Obstet Gynecol*. 2012;39:587-91.
- Naftalin J, Jurkovic D. The endometrial-myometrial junction: a fresh look at a busy crossing. *Ultrasound Obstet Gynecol*. 2009;34:1-11.